




Contents lists available at ScienceDirect

# Interdisciplinary Neurosurgery: Advanced Techniques and Case Management

journal homepage: [www.inat-journal.com](http://www.inat-journal.com)

Case Report &amp; Case Series

## White cord syndrome after non-contiguous double-level anterior cervical decompression and fusion (ACDF): A “no reflow phenomenon”? ☆



Giuseppe Roberto Giammalva, Rosario Maugeri \*, Francesca Graziano, Carlo Gulì, Antonella Giugno, Luigi Basile, Domenico Gerardo Iacopino

Department of Experimental Biomedicine and Clinical Neurosciences, School of Medicine, Neurosurgical Clinic, University of Palermo, Italy

### ARTICLE INFO

#### Article history:

Received 23 November 2016

Revised 1 December 2016

Accepted 4 December 2016

### ABSTRACT

**Study design:** Case report and review of literature.

**Objective:** To report a rare complication of anterior cervical decompression and fusion (ACDF) in a patient with severe cervical cord compression and review of relevant literature.

**Introduction:** The white cord syndrome is a very rare condition characterized by an ischemic-edematous lesion of the spinal cord following a surgical procedure, lacking intra or perioperative surgical or anesthesiological complications.

**Case report:** A 64-years old male affected by a severe cervical stenosis at multiple levels, with voluminous C3–C4 and C5–C6 disc herniations associated to T2-hyperintense myelomalacic area at C3–C4 level was admitted to our Unit of Neurosurgery in July 2015. A double-level anterior cervical decompression and fusion (ACDF) procedure was performed without intraoperative complications and, in the immediate post-operative period, the patient developed a severe motor weakness to four limbs. The post-operative cervical spine MRI revealed an extension of the hyperintensity on the C5–C6 level. In the immediate post-operative course high doses of dexamethasone were administered, in order to treat the secondary spinal damage. The patient was, after few days, transferred to a Rehabilitation Unit where a partial improvement of the motor weakness was gradually observed. We report the second case of this complication in Literature to support the theory of a possible reperfusion injury after a double ACDF. We speculate an ethiologic mechanism similar to a long-term no-reflow phenomenon, likely during the post-ischemic period in myocardial or cerebral infarction.

**Conclusions:** Despite the pathophysiology of non-reflow phenomenon is not widely known, we suspect that an improper blood flow after the double-level discectomy could have led to the changes in medullar hemodynamics.

© 2016 The Authors. Published by Elsevier B.V. This is an open access article under the CC BY-NC-ND license (<http://creativecommons.org/licenses/by-nc-nd/4.0/>).

### 1. Introduction

Anterior cervical decompression and fusion (ACDF) is a technique widely adopted for spinal cord decompression. Despite the overall good clinical outcome associated to this surgical procedure, rare intra and post-operative complications may occur. In most cases, post-operative neurological deficits could be due to late hematomas or to iatrogenic manoeuvres, but in a small percentage they occur in absence of any intraoperative complication [1]. The cause of these events may remain unclear. It has been hypothesized that this neurological

complication could be ascribed to an acute reperfusion mechanism in a severely and chronically damaged spinal cord, maybe due to an oxidative stress [2].

The postoperative appearance of intramedullary hyperintense areas in T2-weighted MR sequences is named as “white cord syndrome” [3]: this has been once previously reported after a double-level discectomy. We report the second case of this complication to support the concept of reperfusion injury after anterior decompression of chronically compressed spinal cord in degenerative spine.

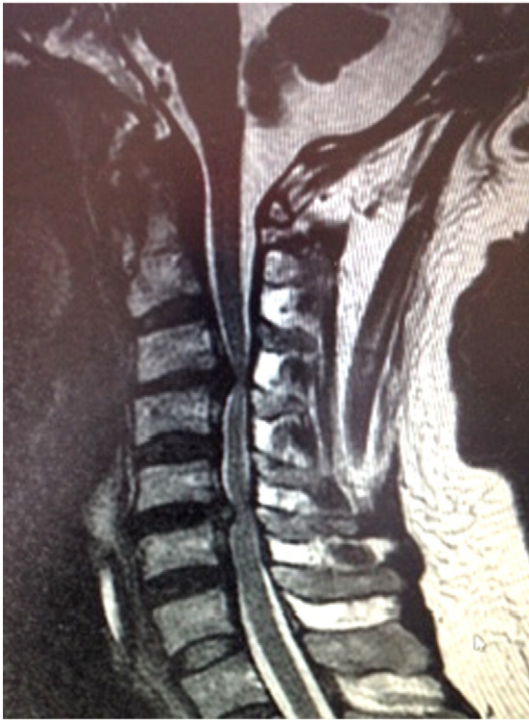### 2. Case report

A 64-years old male patient was admitted to our Neurosurgical Unit with severe neck pain irradiated to both arms, gait disturbance and urinary incontinence. He showed spastic tetraparesis, grip weakness and positive bilateral Hoffman's sign, with a Nurick score of 3 and a Japanese Orthopaedic Association Score (JOA) of 13, Grade I. MRI imaging

☆ Declaration of interest: The Authors report no declarations of interest. This research did not receive any specific grant from funding agencies in the public, commercial, or not-for-profit sectors.

\* Corresponding author at: Department of Experimental Biomedicine and Clinical Neurosciences, School of Medicine, Neurosurgical Clinic, University of Palermo, Via del Vespro 129, 90100 Palermo, Italy.

E-mail address: [rosario.maugeri1977@gmail.com](mailto:rosario.maugeri1977@gmail.com) (R. Maugeri).

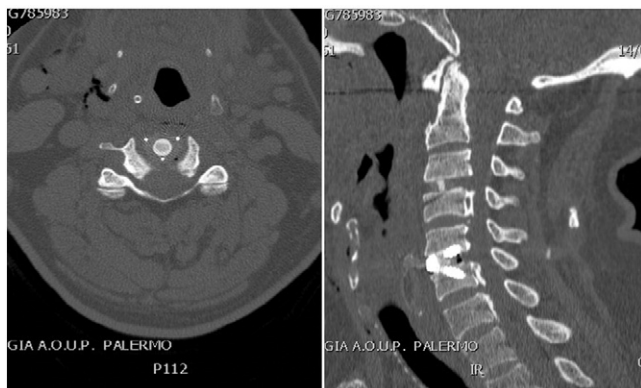


**Fig. 1.** Pre-operative MRI showing C3–C4 and C5–C6 disc herniation and ischemic T2-hyperintense signs of the cervical cord in C3–C4.

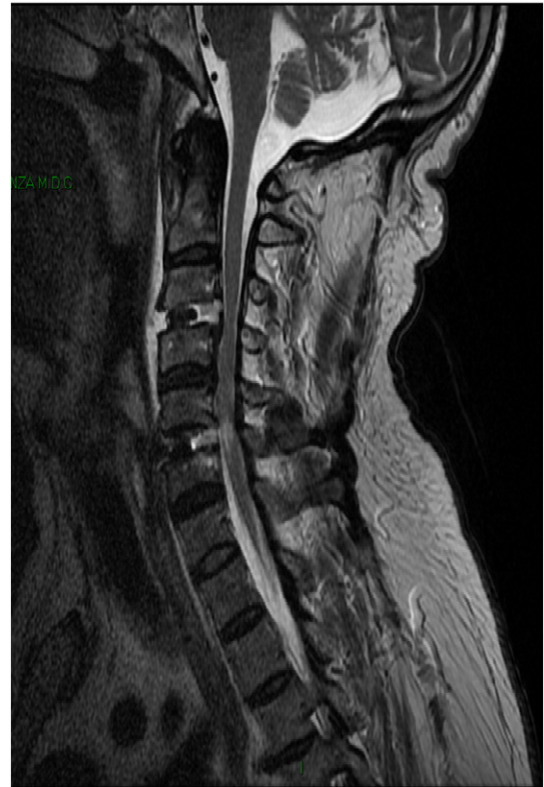documented multiple cervical stenosis with voluminous C3–C4 and C5–C6 disc herniations associated to T2-hyperintense myelomalacic area at C3–C4 level. (Fig. 1).

Patient underwent double-level ACDF with microsurgical discectomy according to Smith-Robinson technique and following anterior arthrodesis, first in C5–C6 with the placement of a titanium cage with intrabody screws (Zero P®, Depuy Synthes – Johnson & Johnson – US), then in C3–C4 level with a stand-alone titanium cage (Cervios®, Depuy Synthes – Johnson & Johnson – US). A diamond drill was used to remove osteophytes in both interbody spaces so to increase spinal cord decompression. An autologous fibrin glue was used to ameliorate haemostasis and fusion [4–5].

No surgical, nor anaesthesiological complications were observed, all neural structures were respected and intra-operative x-ray showed the correct placement of both cages. During the closure time of the superficial planes, somatosensory and motor evoked potentials suddenly decreased in voltage. When awakened, the patient showed a severe tetraparesis with complete paraplegia and severe motor weakness to upper limbs with diffuse spastic hypertonia.



**Fig. 2.** Post-operative CT showing the correct placement of the cervical cages.



**Fig. 3.** Post-operative MRI showing the correct placement of cages, cervical decompression and the extension of ischemic T2-hyperintense signal along the cervical cord on C5–C6.

A neck collar was then placed and an immediate cervical-spine CT imaging confirmed the correct execution of ACDF. (Fig. 2)

A following cervical MRI showed an enlarged T2-hyperintense area in C5–C6 level (Fig. 3).

This ischemic-edematous lesion was supposed to be a case of “white cord syndrome” imputable to a mechanism of improper cord reperfusion. A two-days NASCIS III protocol was then performed.

Three days after, a partial recovery in prehensile strength on the right hand (3/5 Medical Research Council Scale, MRC), a partial recovery in flexion of right arm (2/5 MRC), and in flexion of both legs on thighs (2/5 MRC) were observed.

Seven days after the procedure the patient was transferred to a high specialized Rehabilitation Unit with a Nurick score of 4 and a JOA of 6.

### 3. Discussion

“White cord syndrome” is a very rare condition characterized by an ischemic-edematous lesion of the spinal cord following a surgical procedure, lacking intra or perioperative complications. Even rarely described, this is the second case described after a double level ACDF which betrays a mechanism of reperfusion injury.

Chin and coll. reported the case of a 59-years old patient affected by C5–C6 spinal cord compression, who underwent a double-level ACDF [3]. The operation was complicated by a “white cord syndrome”, causing tetraplegia without any relief to the discharge from Hospital. It was treated by further laminectomy but a partial improvement was seen only in 16-month follow-up after rehabilitation.

In our experience, NASCIS III protocol and intensive intra-hospital rehabilitation led to a partial improvement of the severe tetraparesis in the first week following surgical operation.

In our case, after a multidisciplinary consult, no further decompression, posterior or anterior, was performed because of the lack of significant cervical cord swelling on post-op MRI than pre-operative status.

Even if the aetiopathogenesis of the white cord syndrome is only partially known, we reasonably suspect that, in this case of non-contiguous double-level ACDF, the prior discectomy in C5–C6 level and consequently in C3–C4 level could explain the post-operative white cord syndrome.

Pre-operative MRI showed a T2 hyperintensity in C3–C4 cervical region, due to reduced vascularisation. The sequential decompression, which was firstly performed at C5–C6 level, the less compressed one, and then at C3–C4 level, has probably caused an improper bottom-up haematic reflow along the cervical cord, in this penumbra zone. This has led to the appearance of a second hyperintense area at the C5–C6 level. Unfortunately, this hypothesis could not have been otherwise verified: only the late breaking down of somatosensory, and motor evoked potentials just during closure time, could betray an ongoing ischemic process, not imputable to the cord manipulation.

This complication might be ascribed to a long-term no-reflow phenomenon caused by the reperfusion of a chronically ischemic tissue as a “theft” of blood flow from C5–C6 to the most compressed area, C3–C4, now decompressed. This could be imputable to a variety of mechanisms, such as occlusion of small vessels by the extra-luminal oedema and intra-luminal thrombosis, dysfunction of autoregulatory mechanisms of arteries during the ischemic period, with rapid loss of adenosine triphosphate (ATP), depolarization of cell membranes and accumulation of intracellular  $Ca^{++}$ , and oxidative stress due to the sudden increase of blood pressure after the reperfusion which leads to the overproduction of reactive oxygen species (ROS) and cell death [6–7].

This phenomenon could have determined some changes in hemodynamics of cervical spine: in fact, the double-level C3–C4 and C5–C6 discectomy may have caused a top-down reflow along the arteries of the chronically hypoxic cervical cord that could have led to the worsening of the existing ischemia. A similar mechanism of such complication could be traced also in brain ischemia, in which reperfusion may exacerbate the injury producing a so-called “cerebral reperfusion injury”. This complication may share some pathophysiological pathways with white cord syndrome: in fact, multiple pathological processes are involved, in-

cluding leukocyte infiltration, platelet and complement activation, postischemic hyperperfusion, and breakdown of the blood–brain barrier [6].

However, neither risk factors nor prognostic factors could be yet found and only high doses of dexamethasone and early intensive rehabilitation seemed to be a suitable treatment thus far in case of postoperative white cord syndrome, according to our clinical evidence.

#### 4. Conclusion

Iatrogenic white cord syndrome is a very rare syndrome not widely documented and described in the scientific community. A sharp debate in international literature is encouraged in order to clarify and assess frequency, risks, prognostic factors along with the best therapeutic strategy in cases of post-ACDF white cord syndrome.

#### References

- [1] A. Seichi, K. Takeshita, H. Kawaguchi, S. Nakajima, T. Akune, K. Nakamura, Postoperative expansion of intramedullary high-intensity areas on t2-weighted magnetic resonance imaging after cervical laminoplasty, *Spine* 29 (13) (Jul 1 2004) 1478–1482.
- [2] H. Chen, H. Yoshioka, G.S. Kim, J.E. Jung, N. Okami, H. Sakata, et al., Oxidative stress in ischemic brain damage: mechanism of cell death and potential molecular targets for neuroprotection, *Antioxid. Redox Signal.* 14 (8) (Apr 15 2011) 1505–1517.
- [3] K.R. Chin, J. Seale, V. Cumming, “White cord syndrome” of acute tetraplegia after anterior cervical decompression and fusion for chronic spinal cord compression: a case report, *Case Rep. Orthop.* 2013 (2013) 697918.
- [4] F. Graziano, R. Maugeri, L. Basile, F. Meccio, D.G. Iacopino, Autologous fibrin sealant (Vivostat®) in the neurosurgical practice: Part II: vertebro-spinal procedures, *Surg. Neurol. Int.* 7 (Suppl. 3) (Jan 25 2016) S77–S82, <http://dx.doi.org/10.4103/2152-7806.174894> (eCollection 2016).
- [5] R. Maugeri, G.R. Giammalva, F. Graziano, D.G. Iacopino, May autologous fibrin glue alone enhance ossification? An unexpected spinal fusion, *World Neurosurg.* 95 (2016) 611–612.
- [6] Bay J, Lyden PD. Revisiting cerebral postischemic reperfusion injury: new insights in understanding reperfusion failure, hemorrhage and edema. *int J Stroke* Feb 2015; 10(2): p. 143–152
- [7] I.J. Asiedu-Gyekye, A. Vaktorovich, The “no-reflow” phenomenon in cerebral circulation, *Med. Sci. Monit.* 9 (11) (Nov 2003) BR394–BR397.